

## Research areas of Prof. Dr. C. Weiller

### **Pathophysiology of acute stroke**

The early papers in Archives of Neurology (1989) and Brain (1994) coined the term striatocapsular infarcts due to temporary occlusion of the middle cerebral artery stem and leptomeningeal irrigation of the cortex, an infarct type, which today constitutes the prototype result of thrombolysis, elucidated a cause of cortical symptoms as aphasia in subcortical infarcts and supported the emerging concept of incomplete ischemic infarction (with J. Garcia and N. Lassen in Stroke 1995). These papers formed the basis for recent studies using MRI in selection of patients for thrombolysis (mainly with J. Röther and H. Zeumer) and resulted in current studies on a new view on Diaschisis, a term coined by v. Monakow 1904 as "Betriebsstörung", i.e. temporary dysfunction of a network.

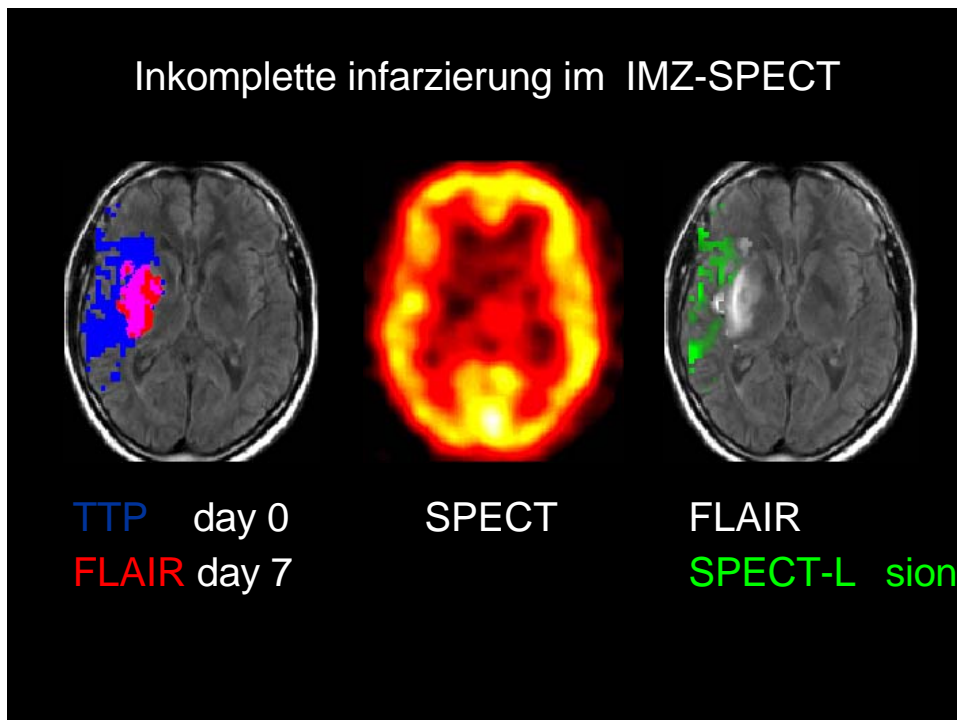
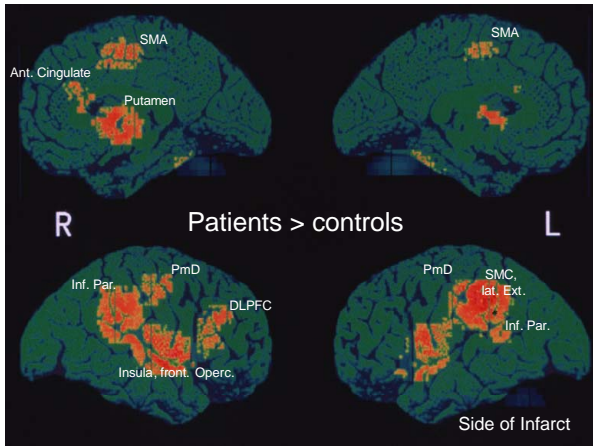


Fig. from D. Saur

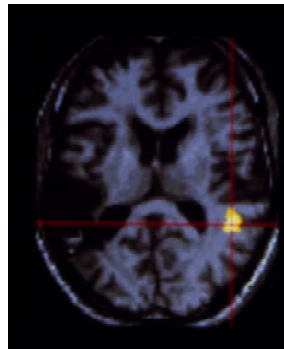
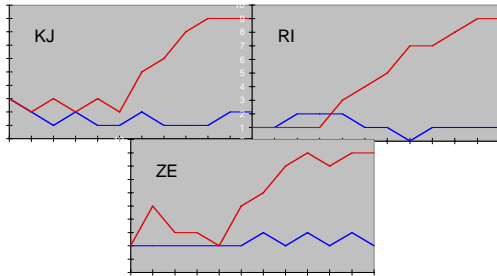
### **Reorganisation of the brain during recovery and rehabilitation**

Three seminal papers set the stage to describe the anatomy of functional reorganisation in the lesioned human brain (Annals Neurol 1992, 1993, 1995, together with RSJ Frackowiak and F. Chollet), reorganisation was shown to be individually different, related to improvement of altered function and can be influenced by training (Musso, 1999), behavioural treatment (Rijntjes, 2005), and pharmacological intervention (Liepert, 2005). The work had a major impact on the rehabilitation community and initiated a new research area. Recently, we defined three stages of brain reorganisation after stroke (Saur, 2006).

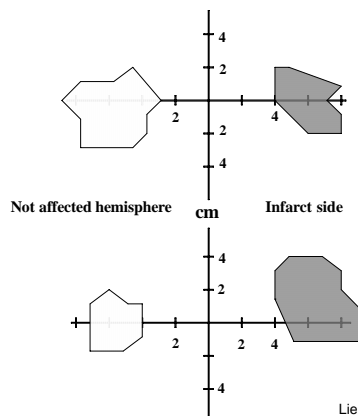


Figs.: increased activation in recovered stroke patients when performing either a finger opposition task (left) or language tasks (right) when compared to normals

Performance of 3 patients in the Token-Test with (red) and without (blue) training

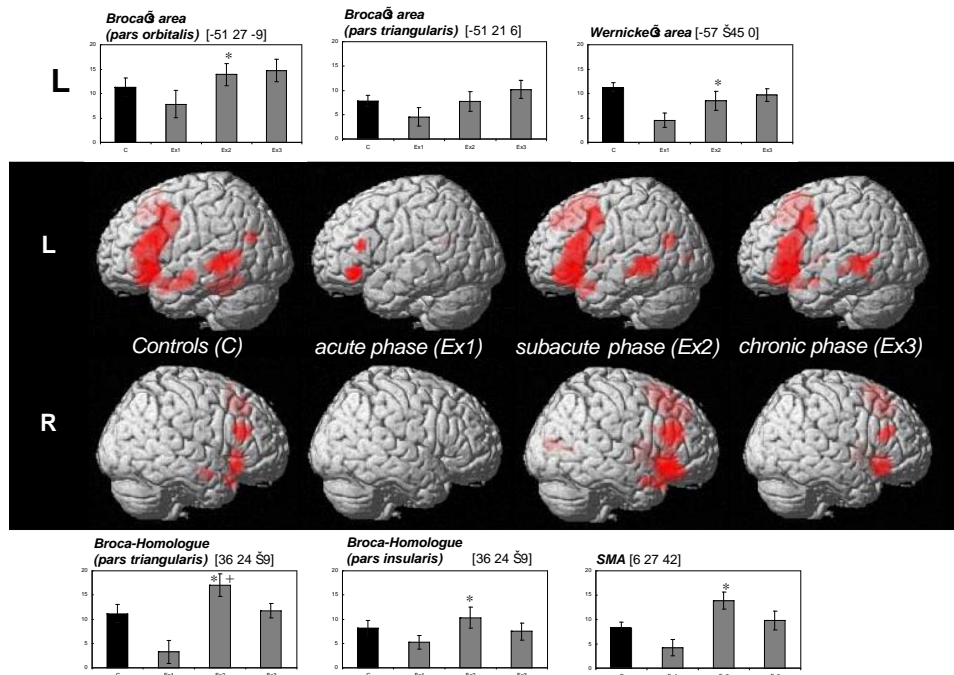


Training induced improvement of comprehension correlates with right hemisphere temporal activation (fig. from M. Musso)



Liepert et al '98

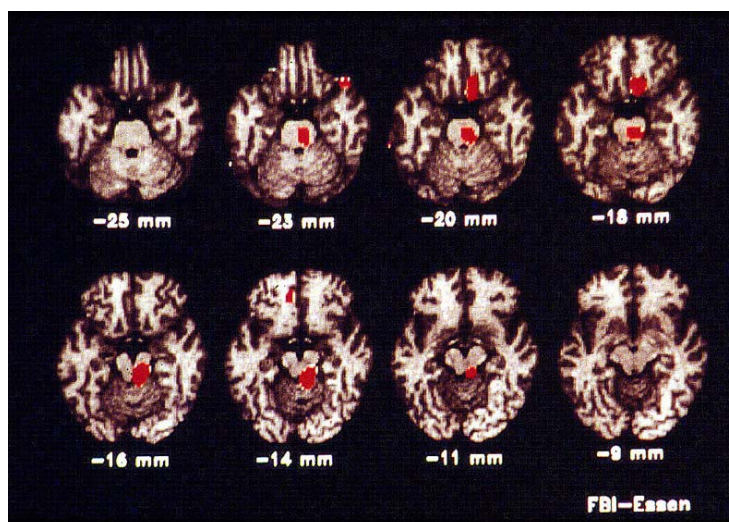
Constraint induced movement therapy increases TMS responsive area in infarcted hemisphere of chronic stroke patients (fig. from J. Liepert)



Three phases of brain reorganisation after stroke in a language comprehension task (fig. D. Saur)

### Brain stem in Migraine

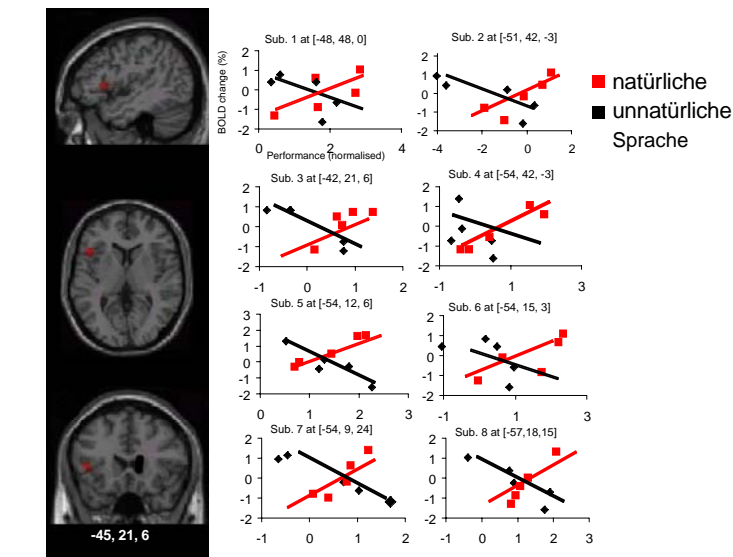
In 1995 a PET study indicated the long sought role of brain stem activation in spontaneous human migraine attacks. This paper is very regularly cited and presents another example of the tediousness of basic research in clinical acute patients, as the findings have only been replicated recently.



Brain stem activation in 9 migraineurs during a spontaneous attack

## Language

The problem of mirroring linguistic concepts in human brain anatomy was followed since the period in London in 1990 (with R. Wise). An early application of voxel-based morphometry in diffusion imaging data illustrated a disconnection of speech-relevant brain areas in developmental stuttering (Sommer, 2002). Learning grammar of foreign languages (i.e. Italian or Japanese) in contrast to learning logical language rules, violating the concepts of "universal grammar" revealed Broca's area in relation to the language instinct (Musso, 2003).



Detecting of natural language rules only correlates with Broca's area activation (Fig. M. Musso)

**Current funding** through BMBF, DAAD, DFG, EU, Medizinische Fakultät Freiburg